

Antiacne and antiblotch activities of a formulated combination of *Aloe barbadensis* leaf powder, *Garcinia mangostana* peel extract, and *Camellia sinensis* leaf extract

This article was published in the following Dove Press journal:
Clinical, Cosmetic and Investigational Dermatology

Neti Waranuch^{1,2}
Preeyawass Phimnuan²
Swanya Yakaew²
Wongnapa Nakyai³
Francois Grandmottet⁴
Churanya Onlom⁵
Jukkarin Srivilai⁶
Jarupa Viyoch^{1,2}

¹Cosmetics and Natural Products Research Center, Faculty of Pharmaceutical Sciences Naresuan University, Phitsanulok 65000, Thailand; ²Department of Pharmaceutical Technology, Faculty of Pharmaceutical Sciences and Center of Excellence for Innovation in Chemistry, Naresuan University, Phitsanulok 65000, Thailand; ³Department of Chemistry, Faculty of Science, Ramkhamhaeng University, Bangkok 10240, Thailand; ⁴Department of Biochemistry, Faculty of Medical Science, Naresuan University, Phitsanulok 65000, Thailand; ⁵Aga Siam, Phitsanulok, 65000, Thailand; ⁶Department of Cosmetic Science, School of Pharmaceutical Sciences, University of Phayao, Phayao 56000, Thailand

Objective: We compared the efficacy of an antiacne hydrogel formulated with a combination of *Aloe barbadensis* leaf extract, *Garcinia mangostana* peel extract, and *Camellia sinensis* leaf extract (AGC) at a ratio of 50:25:1 with a marketed 1% clindamycin gel (CG) formulation on antiacne and antiblotch activities.

Methods: A single-center, parallel-arm, randomized controlled trial was performed from November 2017 to April 2018. Sixty subjects with mild–moderate acne severity according to the the American Academy of Dermatology were enrolled for the study. Outcome end points were total acne lesions (TALs) and acne-severity index (ASI) by counting the inflamed lesions and comedones and skin colors using erythema and melanin values.

Results: For TALs, a decrease ($P<0.0001$) in the number of total inflamed lesions from baseline was evidenced in AGC group, but not in the CG group. Higher reduction in mean ASI in the AGC group was seen than in the CG group. However, there was no statistically significant difference regarding reduction in ASI between the AGC and CG groups. For erythema, a remarked reduction in skin redness from baseline was clearly seen at day 3 ($P<0.05$) in the AGC group. No significant decrease in erythema values from baseline was seen in the CG group. A significant decrease ($P=0.037$) in mean melanin value from baseline was seen in the AGC group after 14 days of twice-daily use, but not in the CG group. Both products were well tolerated, with no reports of severe adverse events.

Conclusion: An anti-acne hydrogel containing a combination of mangosteen rinds, aloe vera gel, and green tea–leaf extracts was superior to 1% clindamycin gel in antiacne and antiblotch activities when measured by TALs and erythema and melanin values.

Keywords: herbal extracts, acne, inflamed lesions, mangosteen rinds, aloe vera gel, green tea leaf

Introduction

Acne vulgaris is an inflammatory skin problem affecting a majority of adolescents. It occurs in the specialized pilosebaceous units on the face, neck, and upper trunk, and can persist for many years. Although it lacks the urgency of a life-threatening condition, its long-term presence can incur significant psychosocial and economic consequences for patients. Standard acne treatments are topical and systemic retinoids and antimicrobial agents, such as clindamycin.¹ Topical antimicrobial acne preparations, which are useful for mild–moderate inflammatory acne, partially exert their beneficial effects by decreasing the follicular population of *Propionibacterium acnes* and

Correspondence: Jarupa Viyoch
Department of Pharmaceutical
Technology, Faculty of Pharmaceutical
Sciences, Naresuan University,
Phitsanulok 65000 Thailand
Tel +665 596 1875
Fax +665 596 3731
Email jarupav@nu.ac.th

influencing the ability of this organism to generate proinflammatory molecules.² However, the widespread use of antibiotics leads to drug-resistance problem, which have been associated with poor response to therapy in some patients.^{3,4} For antiacne therapy, therefore, effectiveness of treatment by limiting the emergence of antibiotic-resistant bacterial populations is an important goal.

The use of herbal products for disease treatment and prevention has increased worldwide over the past decade. The most important reason for this is the belief that they are safe and promote healing and wellness. Although many reports have indicated antimicrobial activities of natural extracts or active agents isolated from several species of plants, almost of them remain untested at the clinical level.^{5,6} In fact, most natural extracts have antimicrobial activity that is considerably less potent than synthetic antibiotics. However, their different modes of biological activity may enhance their antiacne efficacy and be able to reduce *P. acnes* resistance.⁷

Herbal plants, including mangosteen (*Garcinia mangostana*) rinds, aloe vera (*Aloe barbadensis*) gel and green tea (*Camellia sinensis*) leaf (AGC) have been used since ancient times as traditional medicine for various topical applications, and nowadays they are accepted as active ingredients in cosmetic products. Their biological activities, which support potential use in antiacne products, include anti-microbial activity from mangosteen-rind extracts containing xanthenes, anti-inflammatory activity from aloe vera gel containing polysaccharides, and green-tea extracts containing catechins and astringent activity.^{8–15} However, to prove their benefits and assure skin tolerance to the antiacne product developed from such extracts, a clinical study in volunteers should be performed. This study, therefore, aimed to determine clinical efficacy and skin tolerance of topical preparation containing combination of mangosteen rinds, aloe vera gel, and green tea-leaf extracts in human subjects with mild–moderate acne. This was a randomized, single-blind trial with a positive control of 1% clindamycin gel (CG). Primary outcomes were total inflamed lesions and acne-severity index (ASI), and secondary outcomes were skin colors (erythema and melanin) at acne lesions.

Methods

Test products

Products used in this study were a marketed 1% CG formulation and an antiacne hydrogel formulation (Aga Siam,

Phitsanulok, Thailand) containing the AGC combination at a ratio of 50:25:1.

Study design

This study was conducted in accordance with Declaration of Helsinki principles. The study protocol was approved by the institutional review board (0488/60, November 8, 2017) of Naresuan University, Phitsanulok, Thailand. The design of the study was randomized, single blind, with positive control, and was conducted during November 2017 to April 2018 at the Cosmetics and Natural Products Research Center, Naresuan University. Subjects were randomly assigned to receive either the product (AGC) or the benchmark product (CG). Random codes (A or B) were prepared using a random table, and products labeled A or B were further distributed to enrolled subjects by independent staff. Randomization codes were concealed from all investigators until the completion of data analysis. All subjects were followed up for 28 days to measure the number of inflamed lesions and ASI (0.25 comedones + two pustules + papules) by visualization. Moreover, skin redness and melanin were measured to determine erythema for the antiblotch effect of the test products.

Study population

Thai male and female subjects aged 20–45 years with mild–moderate acne determined by a dermatologist were recruited. Mild–moderate acne severity was a score of 2–4 according to the recommendation of the American Academy of Dermatology. Mild or grade 2 acne was defined as 30–40 papules and comedones over a quarter of the face. Moderate or grade 4 acne was defined as about half the face containing a number of papules, comedones, and a few pustules. Subjects were excluded if they were pregnant or planning to become pregnant, lactating, using immunosuppressive or antihistamine medications, had used topical products or medicated cosmetics for acne treatment on the face within 14 days, had used systemic antibiotics for acne treatment within 30 days, had used hormone therapy within 3 months or systemic steroids within 6 months prior to the start of the study, or had a known allergy or sensitivity to cosmetics and/or dermatopharmaceutical products. The number of subjects enrolled was 60 (30 per arm).^{16,17}

Study procedure

Patients were initially recruited through advertising. Subjects were informed of project details by investigators

and asked to sign informed consent before interview for inclusion and exclusion criteria. Subjects were continually recruited until at least 60 had been enrolled.

At day 0, total inflamed facial lesions and facial ASI values were evaluated for baseline. Then, all subjects were randomly assigned to receive either AGC or CG. Subjects were instructed to apply the products to acne lesions twice daily (morning and before bed, after facial cleansing) for 28 days and to continue using the product on the same area until the end of the study. At the end of the study, the number of inflamed lesions and ASI were reevaluated. Moreover, skin color at the lesion sites was evaluated using noninvasive instruments (Mexameter MX18; Courage and Kazaka, Cologne, Germany) on days 2 and 3 for skin redness (erythema value) and days 14 and 28 (melanin value). Photographs of subjects' facial skin were taken and recorded at each visit. Clinical signs and symptoms of skin irritation (itching, vesicles, hyperkeratosis, stinging, redness, erythema, eczema, rash, scaling, and edema) were observed. Subjects were also asked to record a diary on product use and any skin signs and symptoms occurring during the study period. The diaries were evaluated by investigators for compliance and adverse events after study completion. Subject compliance was also monitored by weighing the amount of product remaining.

Verbal assessment of frequency and time of administration was gained on each visit.

Statistical analysis

Descriptive statistics (means \pm SD) were used for collective data. Differences in numbers of inflamed lesions, ASI, and skin color between test products and before vs after use were assessed using unpaired *t*-tests. Statistical significance was set at 0.05.

Results

Sixty Asian subjects signed informed-consent forms and were enrolled in the study. There was no loss to follow-up. Diary evaluation indicated that the subjects used and recorded the time of product used appropriately (twice daily). Therefore, the total 60 subjects completed the study.

Demographic and baseline data

Demographic and baseline characteristics of the subjects are shown in Table 1. The age range of the enrolled subjects was 20–42 years (mean 27.7 \pm 6.4 years). They were predominantly female (39 subjects, 65%). The majority in both groups had acne severity of scale 2 (AGC group, 19 subjects [63.3%]; CG group, 22 subjects

Table 1 Baseline characteristics of subjects

	Test products		Statistical analysis	
	AGC, n=30	CG, n=30	P	Significance
Age (years), mean \pm SD	27.2 \pm 6.5	28.2 \pm 6.3	0.548	None
Sex (n, %)				
Male	8, 26.7	13, 43.3		
Female	22, 73.3	17, 56.7		
Fitzpatrick skin type (n, %)				
III	24, 80	24, 80		
IV	6, 20	6, 20		
Skin colors at acne lesions, mean \pm SEM				
Melanin value, AU	276.6 \pm 8.4	264.2 \pm 9.4	0.329	None
Erythema value, AU	429.1 \pm 13.3	434.2 \pm 12.2	0.779	None
Grading severity, n, %				
Scale 2	19, 63.3	22, 73.3		
Scale 4	11, 36.7	8, 26.7		
Total inflamed lesions, mean \pm SEM	7.9 \pm 1.1	6.8 \pm 0.8	0.422	None
ASI, mean \pm SEM	13.8 \pm 1.8	11.9 \pm 1.2	0.383	None

Abbreviations: AGC, *Aloe barbadensis* leaf extract, *Garcinia mangostana* peel extract, and *Camellia sinensis* leaf extract; CG, clindamycin gel; ASI, acne-severity index.

[73.3%]) and type III skin (AGC group, 24 subjects [80%]; CG group, 24 subjects [80%]). There was no significant difference regarding total inflamed lesions, ASI, or melanin/erythema values between the two groups ($P>0.05$).

Effects of test products on number of inflamed acne lesions and ASI

The antiacne activity of the products on inflamed lesions (papules and pustules) is shown in Table 2 and Figure 1. Mean total inflamed lesions in the AGC and CG groups were 7.9 ± 1.1 and 6.8 ± 0.8 lesions before treatment (day 0), and those after 28 days' treatment were 5.8 ± 0.8 and 5.6 ± 0.8 , respectively. A decrease in acne lesions was seen in both treatment groups and observed in 21 (70%) subjects of each group. No significant difference between the groups was observed. For within-group results for the AGC group, a significant decrease ($P<0.0001$, Table 2) in the number of total inflamed lesions from baseline (Day 0) was seen. No significant decrease was seen within the CG group.

The effect of the test products on the ASI is shown in Table 3 and Figure 2. Mean ASI at baseline was 13.8 ± 1.1 and 11.9 ± 1.2 in the AGC and CG groups, respectively. After 28 days of application, reductions in mean ASI within the AGC and CG groups were not statistically significant ($P>0.05$) compared with baseline ASI; however, reductions were observed in 22 subjects of the AGC group (73.3%) and 21 subjects of the CG group (70.0%).

Effects of test products on skin redness and melanin value of lesions

Mean values of erythema and melanin in the AGC and the CG groups are shown in Tables 4 and 5 and Figures 3 and 4. After application of AGC at acne lesions, a reduction in skin redness from baseline (429.1 ± 13.3) was markedly seen on day 2 (398.7 ± 12.6) and day 3 (388.4 ± 14.9) after application (Table 4 and Figure 3), and a statistically significant decrease was observed at day 3 ($P<0.05$). No significant within-group erythema reduction was seen in the CG group. Within 3 days of application, reduction in erythema was observed in 24 subjects of the AGC group (80%), but only eleven of the CG group (36.7%). Based on mean erythema values, significant differences were initially seen on day 2 ($P=0.017$) and day 3 ($P=0.007$) after

Table 2 Inflamed acne lesions on days 0 and 28 after application of test products

Day	Number of total inflamed lesions, papules, and pustules (mean ± SEM)		Statistical analysis		Statistical analysis
	AGC, n=30	CG, n=30	Within group (compared to baseline)	Between groups	
0	7.9 ± 1.1	6.8 ± 0.8	P<0.0001, AGC, significant P=0.293, CG, not significant	P=0.422, not significant P=0.860, not significant	Between groups P=0.509, not significant
28	5.8 ± 0.8	5.6 ± 0.8			

Abbreviations: AGC, Aloe barbadensis leaf extract; *Garcinia mangostana* peel extract; and *Camellia sinensis* leaf extract; CG, clindamycin gel.

Clinical, Cosmetic and Investigational Dermatology downloaded from https://www.dovepress.com/ by 158.46.144.244 on 31-May-2019
For personal use only.

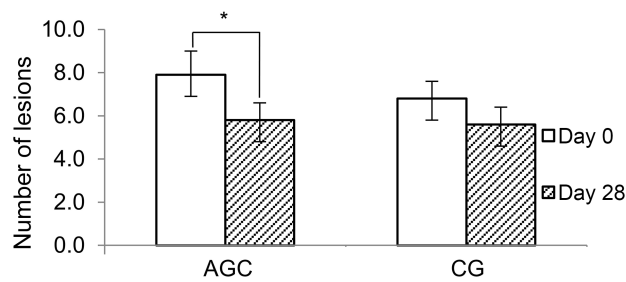


Figure 1 Number of inflamed lesions (papules and pustules, mean \pm SEM) at days 0 and 28 after application.

Notes: After 28 days of twice-daily application on the lesions, a significant decrease was observed in the number of inflamed lesions in the *Aloe barbadensis* leaf extract–*Garcinia mangostana* peel extract–*Camellia sinensis* leaf extract (AGC) group, while none was observed in the 1% clindamycin gel (CG) group. * $P < 0.05$.

application when comparing the AGC and CG groups. In addition, significant differences in skin-color change between the AGC and CG groups were seen at the end of this study (28 days; Table 5).

To assess the depigmentation or antiblotch effect of the products, subjects were instructed to apply the product on the acne lesions continuously until the end of the study. A significant decrease ($P = 0.037$) in mean melanin from baseline was seen in the AGC group after 14 days of twice-daily use, but not in the CG group (Table 5 and Figure 4). In addition, a higher proportion of subjects in the AGC group (26 subjects, 86.7%) showed a decrease in mean melanin value from baseline compared with the CG group (12 subjects, 40%). For between-group results, a marked difference in mean melanin value between the AGC (246.5 ± 9.3) and CG (272.0 ± 10.1) groups was seen after 28 days of application. The percentage change in melanin values from baseline between the AGC (-13.7 ± 2.2) and CG (1.8 ± 2.4) groups was also statistically significant ($P < 0.0001$, Figure 4).

Cutaneous tolerance

During 28 days of twice-daily use, all subjects in both groups reported having no severe peeling, dryness, burning, or itching. Both test products were well tolerated at the cutaneous level.

Compliance

Compliance of subjects was assessed by comparing product weights after use. Moreover, subjects were asked to keep diaries as a record of product use. Mean weights of AGC and the CG used were 41.0 ± 21.3 g and 43.5 ± 16.8 g, respectively. There was no significant difference between the groups. Diary evaluation showed that $>80\%$

Table 3 ASI on days 0 and 28 after application of test products

Day	ASI, mean \pm SEM		Statistical analysis		Statistical analysis
	AGC, n=30	CG, n=30	Within group (compared to baseline)	Between groups	
0	13.8 \pm 1.1	11.9 \pm 1.2	—	—	—
28	10.6 \pm 1.3	10.1 \pm 1.2	$P < 0.155$, AGC, not significant $P = 0.293$, CG, not significant	$P = 0.383$, not significant $P = 0.779$, not significant	$P = 0.482$, not significant

Abbreviations: ASI, acne-severity index; AGC, *Aloe barbadensis* leaf extract, *Garcinia mangostana* peel extract, and *Camellia sinensis* leaf extract; CG, clindamycin gel.

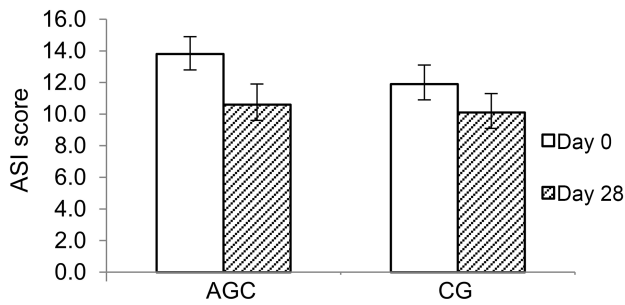


Figure 2 Acne-severity index (ASI; mean ± SEM) on days 0 and 28 after application. **Note:** After 28 days of twice-daily application, no significant decrease was observed in either the *Aloe barbadensis* leaf extract–*Garcinia mangostana* peel extract–*Camellia sinensis* leaf extract (AGC) or 1% clindamycin gel (CG) group.

of the subjects recorded the time of product use appropriately.

Discussion

Generally, topical comedolytics and antibiotics are the common therapy for acne treatment. However, they have several adverse effects, such as skin irritation, peeling, burning, and abnormal skin pigmentation.^{18,19} This calls for an effective antiacne regimen with minimal undesirable outcomes. Research has shown successful acne treatment with botanical products^{17,20–22} used alone or in combination. Many of them are less potent than synthetic antibiotics, but their different modes of biological activities, such as anti-inflammation and antibacterial, may enhance antiacne efficacy and skin tolerance, as well as decrease the prevalence of antibiotic resistance. In the present study, compared to 1% CG, the AGC combination (50:25:1) clinically demonstrated antiacne and depigmenting activities. We found that after 28 days' treatment, a decrease in acne lesions was seen in both the CG and AGC groups. However, a statistically significant decrease in the number of inflamed lesions from day 0 was seen in the AGC group. Such a decrease possibly resulted from multi-functional activities — antimicrobial, anti-inflammatory, and astringent — of the combined herbal extracts. Moreover, green-tea and mangoste-n rind extracts have been reported to be potent antioxidants.^{12–15,23,24} There have been reports indicating a relationship between the inflammation process and *P. acnes*-induced reactive oxygen-species generation, and use of topical antioxidants minimized inflammation and acne severity.^{25–27} With regard to ASI, even though a higher reduction in mean ASI in the AGC group (–3.1 ±1.3) was seen compared to the CG group (–1.8±1.3), the reduction in neither group was statistically significant vs baseline. To calculate ASI scores, uninflamed acne was also used in the formula.^{16,17} This may have resulted in an

Table 4 Erythema at acne lesions on days 2 and 3 after application of test products

Day	Erythema value (AU), mean ± SEM		Statistical analysis		Statistical analysis
	AGC, n=30	CG, n=30	Within group (compared to baseline)	Between groups	
0	429.1 ± 13.3	434.2 ± 12.2	—	—	—
2	398.7 ± 12.6	441.2 ± 11.9	P=0.102, AGC, not significant P=0.683, CG, not significant	P=0.779, not significant P=0.017, significant	1.5 ± 1.2 P<0.0001, significant
3	388.4 ± 14.9	441.4 ± 11.7	P=0.046, AGC, significant P=0.672, CG, not significant	P=0.007, significant	1.4 ± 1.5 P<0.0001, significant

Abbreviations: AGC, *Aloe barbadensis* leaf extract, *Garcinia mangostana* peel extract, and *Camellia sinensis* leaf extract; CG, clindamycin gel.

A small number of subjects may provide results that would be inconsistent with data from a larger number of subjects. Additionally, the short duration of the study may have restricted our ability to detect any significant adverse events. Further studies should be performed with a larger samples and of longer duration to confirm the beneficial antiacne and depigmentation effects of the AGC product.

Conclusion

Clinical efficacy and skin tolerance of the AGC topical preparation compared with a 1% clindamycin (CG) available on the market were assessed in human subjects with mild–moderate acne. Both AGC and CG reduced the number of inflamed lesions after 28 days of treatment. However, a significant reduction from baseline was seen only in the AGC group. Significant reductions in erythema and melanin were observed in the AGC group at days 3 and 14 of application, respectively. No significant adverse effects were seen in the AGC or CG group during 28 days of application.

Acknowledgments

We thank the Thailand Center of Excellence for Life Sciences (public organization), Ministry of Science and Technology, and Aga Siam Company Limited, Thailand for financial support of the research. We also thank the Center of Excellence for Innovation in Chemistry (PERCH-CIC) and Office of the Higher Education Commission, Thailand for facility support. We would like to acknowledge Assistant Professor Prateep Warnissorn, MD, PhD, Division of Dermatology, Faculty of Medicine, Naresuan University for generous assistance in clinical evaluation and subject screening.

Disclosure

PP, NW, FG and JV report grants from Aga Siam during the study. The other authors report no conflicts of interest in this work.

References

- Layton AM. A review on the treatment of acne vulgaris. *Int J Clin Pract.* 2006;60:64–72. doi:10.1111/j.1368-5031.2005.00695.x
- Krauthaim A, Gollnick HPM. Acne: topical treatment. *J Clin Dermatol.* 2004;22:398–407. doi:10.1016/j.clindermatol.2004.03.009
- Coates P, Vyakarnam S, Ravenscroft JC, Jones CE, Covv JH, Cunliffe WJ. Prevalence of antibiotic-resistant propionibacteria on the skin of acne patients: 10-year surveillance data and snapshot distribution study. *Br J Dermatol.* 2002;146:840–848.
- Eady EA, Gloor M, Leyden JJ. Propionibacterium acnes resistance: a worldwide problem. *Dermatology.* 2003;206:54–56. doi:10.1159/000067822
- Cowan MM. Plants products as antimicrobial agents. *Clin Microbiol Rev.* 1999;12:564–582.
- Viyoch J, Pisutthanan N, Faikrea A, Nupangta K, Wangtorpol K, Ngokkuen J. Evaluation of in vitro antimicrobial activity of Thai basil oils and their micro-emulsion formulas against propionibacterium acnes. *Int J Cosmet Sci.* 2006;28:125–133. doi:10.1111/j.1467-2494.2006.00308.x
- Martin KW, Ernst E. Herbal medicines for treatment of bacterial infections: a review of controlled clinical trials. *J Antimicrob Chemother.* 2003;51:241–246.
- Palakawong C, Sophanodora P, Pisuchpen S, Phongpaichit S. Antioxidant and antimicrobial activities of crude extracts from mangosteen (*Garcinia mangostana* L.) parts and some essential oils. *Int Food Res J.* 2010;1:583–589.
- Geetha RV, Roy A, Lakshmi T. Evaluation of anti bacterial activity of fruit rind extract of *Garcinia mangostana* Linn. on enteric pathogens-An in vitro study. *Asian J Pharm Clin Res.* 2011;4:115–118.
- Inpanya P, Faikruea A, Ounaron A, Sittichokechaiwut A, Viyoch J. Effects of the blended fibroin/aloë gel film on wound healing in streptozotocin-induced diabetic rats. *Biomed Mater.* 2012;7:035008. doi:10.1088/1748-6041/7/3/035008
- Benson KF, Newman RA, Jensen GS. Antioxidant, anti-inflammatory, anti-apoptotic, and skin regenerative properties of an aloë vera-based extract of Nerium oleander leaves (nae-8®). *Clin Cosmet Invest Dermatol.* 2015;8:239–248.
- Chacko SM, Thambi PT, Kuttan R, Nishigaki I. Beneficial effects of green tea: a literature review. *Chinese Med.* 2010;5:13. doi:10.1186/1749-8546-5-13
- Jindarat S. Xanthones from mangosteen (*Garcinia mangostana*): multi-targeting pharmacological properties. *J Med Assoc Thai.* 2014;97:S196–S201.
- Bhalang K, Thunyakitpisal P, Rungsirisatean N. Acemannan, a polysaccharide extracted from aloë vera, is effective in the treatment of oral aphthous ulceration. *J Altern Complement Med.* 2013;19:429–434. doi:10.1089/acm.2012.0164
- Sierra-García GD, Castro-Ríos R, González-Horta A, Lara-Arias J, Chávez-Montes A. Acemannan, an extracted polysaccharide from aloë vera: a literature review. *Nat Product Commun.* 2014;9:1217–1221.
- Shahmoradi Z, Irají F, Siadet AH, Ghorbaini A. Comparison of topical 5% nicotinamide gel versus 2% clindamycin gel in the treatment of the mild-moderate acne vulgaris: a double-blinded randomized clinical trial. *J Res Med Sci.* 2013;18:115–117.
- Enshaieh S, Jooya A, Siadet AH, Irají F. The efficacy of 5% topical tea tree oil gel in mild to moderate acne vulgaris: a randomized, double-blind placebo-controlled study. *Indian J Dermatol Venerol Leprol.* 2017;73:22–25.
- Castro GA, Oliveira CA, Mahecha GA, Ferreira LA. Comedolytic effect and reduced skin irritation of a new formulation of all-trans retinoic acid-loaded solid lipid nanoparticles for topical treatment of acne. *Arch Dermatol Res.* 2011;303:513–520. doi:10.1007/s00403-011-1130-3
- Kawashima M, Nagare T, Doi M. Clinical efficacy and safety of benzoyl peroxide for acne vulgaris: comparison between Japanese and Western patients. *J Dermatol.* 2017;44:1212–1218. doi:10.1111/1346-8138.13996
- Orafidiya LO, Agbani EO, Oyedele AO, Babalola OO, Onayemi O, Aiyedun FF. The effect of aloë vera gel on the anti-acne properties of the essential oil of *Ocimum gratissimum* Linn leaf – A preliminary clinical investigation. *Int J Aromather.* 2004;14:15–21. doi:10.1016/j.ijat.2003.12.005
- Hajheydari Z, Saeedi M, Morteza-Semnani K, Soltani A. Effect of aloë vera topical gel combined with tretinoin in treatment of mild and moderate acne vulgaris: a randomized, double-blind, prospective trial. *J Dermatolog Treat.* 2014;25:123–129. doi:10.3109/09546634.2013.768328

22. Sriviriyakul K, Sithisarn P, Managit C, Trithossadech P, Lueangarun S. Clinical efficacy of topical mangosteen extract nanoparticle loaded gel compared with 1% clindamycin gel in the treatment of mild to moderate acne vulgaris. *Thai J Pharm Sci.* 2017;41:S121–S124.
23. Camouse MM, Domingo DS, Swain FR, et al. Topical application of green tea and white tea extracts provides protection from solar-simulated ultraviolet light in human skin. *Exp Dermatol.* 2009;18:522–526. doi:10.1111/j.1600-0625.2008.00818.x
24. Fitri EW, Anwar AI, Djawad K, Seweng A, Changara H, Alam G. The effectiveness of topical mangosteen pericarp extract on the collagen of mice skin exposed to ultraviolet B. *Am J Clin Exper Med.* 2016;4:88–93. doi:10.11648/j.ajcem.20160403.19
25. Grange PA, Chéreau C, Raingeaud J, et al. Production of superoxide anions by keratinocytes initiates *P. acnes*-induced inflammation of the skin. *PLoS Pathog.* 2009;5:e1000527. doi:10.1371/journal.ppat.1000706
26. Li ZJ, Choi DK, Sohn KC, et al. *Propionibacterium acnes* activates the NLRP3 inflammasome in human sebocytes. *J Invest Dermatol.* 2014;134:2747–2756. doi:10.1038/jid.2014.221
27. Kistowska M, Gehrke S, Jankovic D, et al. IL-1 β drives inflammatory responses to *propionibacterium acnes* in vitro and in vivo. *J Invest Dermatol.* 2014;134:677–685. doi:10.1038/jid.2013.438

Clinical, Cosmetic and Investigational Dermatology

Dovepress

Publish your work in this journal

Clinical, Cosmetic and Investigational Dermatology is an international, peer-reviewed, open access, online journal that focuses on the latest clinical and experimental research in all aspects of skin disease and cosmetic interventions. This journal is indexed on CAS.

The manuscript management system is completely online and includes a very quick and fair peer-review system, which is all easy to use. Visit <http://www.dovepress.com/testimonials.php> to read real quotes from published authors.

Submit your manuscript here: <https://www.dovepress.com/clinical-cosmetic-and-investigational-dermatology-journal>